

Anatomy of the Bronchial Tree

The bronchial tree begins at the bottom of the trachea and divides into 2 primary bronchi, 1 for each lung. The location of this division is known as the **bifurcation** and is where the left and right primary bronchi begin. The left and right lungs are divided into lobes by 1 or more deep grooves called **fissures**. Each lobe contains 1 bronchus branch. The right lobe of the lung, which has 3 lobes, contains 3 branches. The left lobe of the lung, which has 2 lobes, contains 2 branches. These lobes are called secondary (lobar) branches. The detailed anatomy of the lungs and bronchial tree is illustrated in Figure 5.

Within the lung, secondary (lobar) bronchi are further divided into tertiary (segmental) bronchi, of which there is 1 segmental bronchus per **bronchopulmonary segment**.²⁰ The tertiary bronchi further subdivide and go on to form bronchioles, which subdivide further into smaller and smaller segments.²⁰ After the last of these subdivisions, the resulting airway passages are termed terminal bronchioles. The terminal bronchioles are the final branches of the bronchi and

DID YOU KNOW?

Gas exchange in the alveoli

The respiratory bronchioles give rise to alveolar sacs, which contain numerous alveoli. The alveoli are the primary site of gas exchange between the lungs and the blood. Following inhalation, oxygen from the air diffuses from the alveoli into the blood. Meanwhile, carbon dioxide diffuses in the opposite direction. Diffusion occurs passively across a permeable membrane from an area of higher concentration to an area of lower concentration. This occurs due to the differences in the partial pressures of these gases in the alveoli and adjacent blood supply. Upon inhalation, the atmospheric air enters the lungs. Subsequently, the air in the alveoli is higher in oxygen and lower in carbon dioxide than the gas dissolved in the venous blood supplying the alveoli. Arterial blood contains oxygenated blood from the lungs to the heart before it is pumped to the various tissues of the body.²²

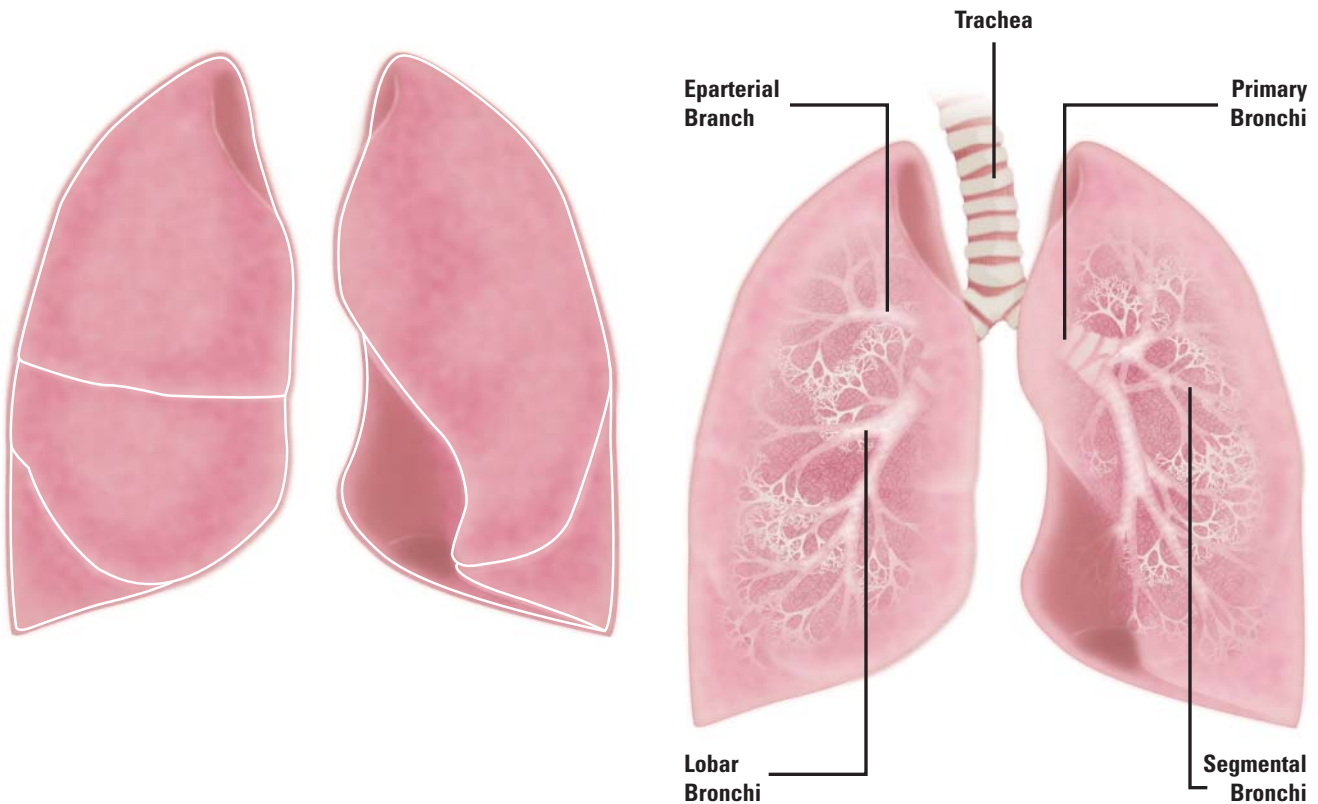


Figure 5: Anatomy of the Lungs and Bronchial Tree

A. Anatomy of the lungs demonstrating the fissures defining the lobes of the lungs. B. Anatomy of the bronchial tree demonstrating the trachea, bifurcation, **eparterial branch**, right and left primary bronchi, lobar bronchi, and segmental bronchi.